

## Ultrasound assessment of polycystic ovary syndrome (PCOS)

*Yakubov Daniyori Javlanovich*

*Akhrorov Bakhodir, son of Akbar*

*1. Samarkand State Medical University Assistant of the Department of Medical Radiology Samarkand, Uzbekistan*

*2. Samarkand State Medical University Clinical resident of the Department of Medical Radiology Samarkand, Uzbekistan*

**Abstract** This article highlights modern approaches to the assessment of polycystic ovary syndrome (PCOS) using ultrasound diagnostics. PCOS is one of the most common endocrine disorders in women of reproductive age and is characterized by hormonal imbalance, anovulation, and structural changes in the ovaries.

**Keywords:** polycystic ovary syndrome, ultrasound, ultrasonography, ovaries, follicles, Doppler

Ovary polycystic ovary syndrome syndrome (PTTS) reproductive aged in women the most wide widespread endocrine and gynecological from diseases one This is syndrome hormonal imbalance , anovulation , menstruation cycle violation , excess androgens ( hirsutism ) and in the ovaries many follicles existence with described .

PTTS is not only reproductive function breaks , maybe metabolic processes and women's general also noticeable on health impact shows , this because of the disease early determination and right diagnosis to put big importance has . Last in the diagnosis of PTTS in the years ultrasound Ultrasound examination (UZI) is one of the main instrumental methods one as wide is being used . Using ultrasound ovaries size , morphological structure , follicles number and location is determined

Especially the periphery along located many numerical follicles — “ pearl” Shodasi ” (string of pearls) symbol — PTTS the most characteristic ultrasound appearance as Also , Doppler examination through ovary in the stroma blood flow is measured , this and of the disease morphological and functional aspects

assessment opportunity gives . Scientific research this ultrasound shows that diagnostics PTTS early diagnosis , disease weight level assessment and right differential diagnosis in the past reliable and comfortable method Therefore , ultrasound is based on assessment PTTS clinical to practice integration to do and patients effective treatment strategy when choosing big importance has . This article PTTS ultrasound using evaluation modern methods , basic diagnostic criteria and their clinical importance systematic accordingly to illuminate focused .

### **Literature comment**

Urachus Ovary polycystic ovary syndrome syndrome (PTTS) ultrasound using assessment issues according to last in years many scientific research conducted . Research this shows that PTTS in determining ultrasound inspection the most effective and safe instrumental methods one to be , to be sick early in stages determination opportunity ( Balen et al., 2003; Rotterdam ESHRE/ASRM, 2004).

Using ultrasound ovaries size , morphological structure , follicles number and their location is determined . Especially , peripheral in a way located many numerical follicles — “ pearl” Shodasi ” (string of pearls) symbol — PTTS the most characteristic ultrasound appearance as acceptance will be done and diagnostic importance high ( Azziz et al., 2016).

Also, Doppler ultrasound research ovary in the stroma blood flow assessment opportunity This gives PTTS other of cases — multifollicular ovaries , functional cysts or hormonal disorders as a result to the surface coming morphological from changes — in differentiation important importance profession (Crichton et al., 2012) .Research this shows that the combination of ultrasound and Doppler PTTS early diagnosis , disease weight level assessment and patients right treatment strategy when choosing high diagnostic accuracy ( Li et al., 2018).

From this besides , literature analysis with PTTS related morphological changes and follicles number and location reproductive results with directly dependence For example , follicles many and stromal blood of the flow increase pregnancy opportunities in evaluation and reproductive function forecast in doing

important indicator as is used ( Teede et al., 2018). With this together , some in research ultrasound criteria PTTS clinical to the signs dependency analysis done , this and diagnostics process further more precisely to do help This view gives by sight , ultrasound and Doppler diagnostics PTTS in determining main and reliable method It is considered a patient . early diagnosis , disease clinical weight level evaluation , differential diagnosis clear to put and individual treatment strategy working on the way out big importance has . With this together , research through ultrasound taken information other diagnostic methods with — laboratory and hormonal analyses with — integration also shows the importance of this and clinical in practice complex approach provides .

In general generally , literature analysis this shows that ultrasound and Doppler diagnostics PTTS detection , disease monitoring and individual treatment of patients plan working exit for main and reliable tool is considered , this and clinical practice and scientific in research his/her importance further increases .

### **Purpose**

This of the research purpose ovary polycystic ovary syndrome syndrome (PTTS) ultrasound using assessment methods systematic accordingly study and their clinical diagnostic value from determining consists of . Research within ovaries morphological changes , follicles number , diameter and location , as well as Doppler examination via stromal blood flow analysis is done . Through this PTTS early in stages diagnosis , disease level assessment and differential diagnosis clear in the past ultrasound and Doppler methods efficiency is evaluated .

The research additional purpose clinical in practice ultrasound and Doppler examinations reproductive function assessment , patients pregnancy opportunities forecast to do and individual treatment strategy working on the way out application opportunities is to determine . With this together with PTTS related morphological and functional of changes ultrasound through assessment , disease monitoring and far term the results forecast in doing reliable diagnostic tool that Research also , ultrasound and Doppler results laboratory and hormonal analyses with integration

through PTTS complete and complex diagnostics to do also explores the possibilities. In general in short , research PTTS early to determine , its clinical weight level assessment , patients right differential diagnosis with determination and individual treatment strategy working on the way out ultrasound and Doppler methods importance scientific basically to confirm focused .

### **Materials and methods**

This research ovary polycystic ovary syndrome syndrome (PTTS) ultrasound using to evaluate Research retrospective in the years 2020–2025 during the city of Samarkand Ultrasound examination in hospitals held patients to the information PTTS was detected in a total of 85 patients : 50 classic PTTS, 20 people multifollicular ovaries , 10 in each functional cysts and 5 of them other hormonal disorders with related changes observed . Patients age from 18 to 42 years old divided , average Age  $26 \pm 6$  years organization Women make up 85 (100%) did .

Clinical complaints between menstruation cycle disorders 68 (80%), hirsutism 42 (49%), pregnancy difficulties 35 (41%) and in the stomach Pain was observed in 28 (33%) patients . Ultrasound examination ovary size average  $12 \pm 3$  ml, follicles number  $15 \pm 4$ , peripheral located follicles and in 72 (85%) patients Stromal blood was detected on Doppler examination . flow increase in 60 (71%) patients record was done .

Results following parameters according to analysis done : ovary size , follicles number and diameter of follicles location , stromal blood flow , clinical complaints and laboratory indicators . Obtained information statistic in terms of analysis was done , average values and standard hard work was calculated .

<b>Indicator</b>	<b>Quantity (n)</b>	<b>Percentage (%)</b>
<b>Total patients</b>	85	100
<b>Age ( mean <math>\pm</math> SD)</b>	26 $\pm$ 6	—
<b>Clinical characters</b>		
<b>Menstrual cycle violation</b>	68	80
<b>Hirsutism</b>	42	49
<b>Pregnancy difficulties</b>	35	41
<b>In the womb pain</b>	28	33

Ultrasound inspection convex using a sensor (3–5 MHz) done increased . Inspection during ovary size and morphology of follicles number , diameter and location , peripheral " pearl " of follicles "string of pearls " symbol existence , internal echostructure ( liquid , partial hard ), wall thickness and contour flatness and stromal blood in Doppler mode flow and blood vein branching was evaluated .

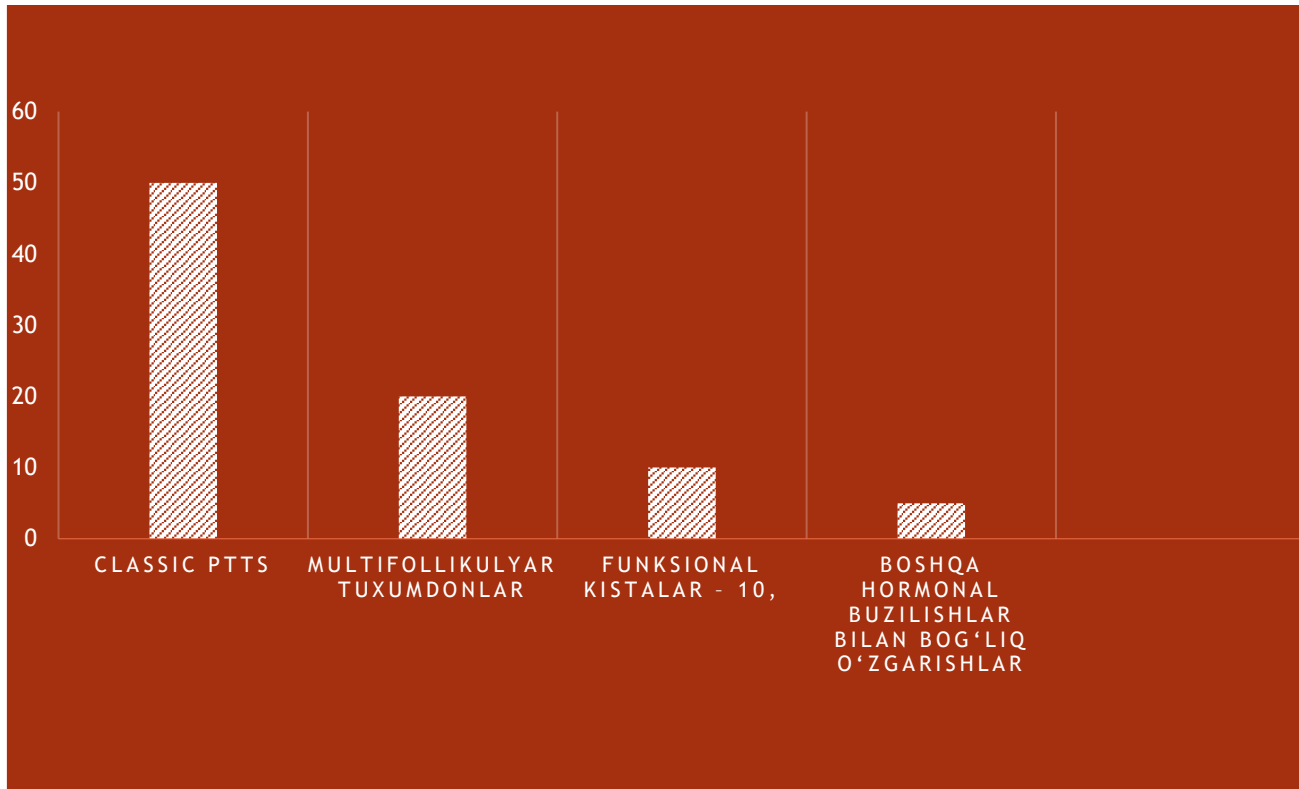
Results following diagrams with visualization was done : in the ovaries morphological of changes distribution :

Classic PTTS – 50,

Multifollicular ovaries – 20,

Functional cysts – 10,

Other hormonal disorders with related changes – 5.



### Analysis method :

Data in SPSS 25 program descriptive statistics using analysis Results average values , standard hard work , relative and percent in appearance presented Ultrasound and Doppler results with clinical signs , follicles number and ovary morphology between dependency correlational analysis through was studied . Also, the data reliability and statistic significance at the  $p < 0.05$  level was evaluated .

### Ethics:

Patients personal information secret saved , research local boot commission by approved .

### Discussion

This research results ultrasound shows that and Doppler examination ovary polycystic ovary syndrome in the diagnosis of PTTS syndrome main and reliable diagnostic method is . Convex sensor using taken information ovary size of follicles number , diameter and peripheral location according to clinical characters with solid connection showed .

Research results previously held scientific research with in harmony divided into , classic PTTS , multifollicular ovaries and functional cysts between morphological the differences clear designation opportunity ( Balen et al., 2003; Azziz et al., 2016). Also, stromal blood flow in Doppler examination of the flow increase many in patients observed , this is with PTTS related hormone and ovulatory of violations physiological basis confirms and reproductive function in evaluation important diagnostic indicator as service The follicles number and peripheral location pregnancy opportunities forecast also great in making importance has individual treatment of patients strategy working on the way out guide gives .

Results this ultrasound shows that and Doppler examination not only PTTS determination with not limited to , but patient monitoring , reproductive potential assessment and treatment efficiency also effective in monitoring tool is considered . Research convex sensor with local in hospitals done increased Although the results are global studies with compared to high reliability and repetition opportunity showed . From this except for , information analysis PTTS morphological and functional changes clinical characters with tie opportunity gave , this and in the future Individual approach to patients with treatment , reproductive function optimization and of the disease weight level determination for scientific basis creates .

With this together , research PTTS ultrasound using evaluation clinical and diagnostic importance strengthened and in the future Individual approach to patients with treatment , monitoring and reproductive potential forecast to do opportunities further to increase service does ..

### **Conclusion**

This research results ovary polycystic ovary syndrome Convex syndrome (PTTS) sensor using ultrasound and Doppler examination through evaluation clinical and diagnostic importance The study shows that in Samarkand in 2020–2025 in hospitals retrospective in a way was held , 85 people patient analysis The data were analyzed

in SPSS 25 . descriptive statistics and correlational analysis using studied , ultrasound and Doppler results with clinical signs , follicles number , diameter and ovary morphology between dependency determined of the research scientific importance increased . Results this showed that convex sensor using ovary size and morphology detection , follicles number and peripheral location assessment PTTS early in determining high diagnostic accuracy gives .

Stromal blood on Doppler examination flow increase with PTTS related hormone and ovulatory of violations physiological basis confirms and reproductive function forecast in doing important indicator Clinical complaints , including menstruation cycle disorder , hirsutism and pregnancy difficulties with ultrasound results between correlational dependency Individual approach to patients with treatment and monitoring opportunity The study also showed that classic PTTS , multifollicular ovaries and functional cysts ultrasound through clear separation it is possible , this and differential diagnosis and treatment strategy working on the way out important importance profession will reach .

Research convex sensor using local in hospitals done increased Although the results are global studies with reliability in comparison and repetition opportunity showed . In general in this case , research PTTS ultrasound and using Doppler evaluation clinical , diagnostic and reproductive importance strengthened , patients early identification , individual treatment strategy working exit and reproductive potential forecast to do opportunities expands and clinical in practice this of methods main and reliable tool as application confirms .

#### Literature list

1. Balen AH, Laven JS, Tan S -L, Dewailly D *Ultrasound assessment of the polycystic ovary: international consensus definitions* . Hum Reprod Update. 2003;9(6):505 -14.
2. Zhu R -Y, Wong YC, Yong EL *Sonographic evaluation of polycystic ovaries* . Best Pract Res Clin Obstet Gynecol . 2016 Nov;37:25 -37.

3. Bachanek M, Abdalla N, Cendrowski K, Sawicki W *Value of ultrasonography in the diagnosis of polycystic ovary syndrome - literature review* . J Ultrasound . 2015 Dec;15(63):410 -22.
4. *Ultrasonographic criteria in the diagnosis of polycystic ovary syndrome: a systematic review and diagnostic meta- -analysis (1900–2023)*.
5. Di Michele S, Fulghesu AM, Pittui E, et al *Ultrasound assessment in PCOS diagnosis: from origins to future perspectives — a comprehensive review* . Biomedicines . 2025.
6. Teede HJ, Misso ML, Costello MF, et al *International PCOS guideline: 2018 update — ( in part to analysis included references ) — diagnostic criterion and the role of UZI* .
7. Dewailly D, Gronier H, Poncelet E, et al *Definition and significance of polycystic ovarian morphology in PCOS diagnosis* . ( many in the comments to the language taken )
8. *The value of ultrasonography features in diagnosis and prediction of reproductive -metabolic dysfunctions in PCOS: a narrative review* . Middle East Fertility Society Journal. 2025.
9. *The sonographic association between PCOS and infertility: systematic review* . ( medical and diagnostic analysis )
10. Pache TD, van Santbrink EJ, Jonard S et al — referenced in PCOS ultrasound consensus (Rotterdam, AE -PCOS) analysis doer research .